



Case Report

Rejuvenating the smile with dental and gingival harmony- A case report

Mamta Kumari¹, Abhishek Kumar Gupta^{2,*}, Rekha Gupta²

¹Maulana Azad Institute of Dental Sciences, New Delhi, India

²Dept. of Prosthodontics, Maulana Azad Institute of Dental Sciences, New Delhi, India



ARTICLE INFO

Article history:

Received 21-11-2020

Accepted 26-11-2020

Available online 02-12-2020

Keywords:

Smile design

Digital smile design

Mock up

Gingival zenith

Veneers.

ABSTRACT

Appearance of dentition is of concern to a large people seeking dental treatment. People are giving a lot importance to the red and white aesthetics i.e the teeth and the gums. Apart from just colour of these dental components, harmony within these structures is of utmost important which includes shade, shape and size of teeth along with gingival esthetics. Gingival esthetics includes gingival architecture along with its colour. Principles of esthetics must be followed for beautiful result. With introduction of digital smile designing, work on improving smile became more predictable. Using the technology, it becomes easy to guide best esthetics possible. Communication with patient showing their future result is possible. Due to high cost and need for special software makes it impossible to use for every patients seeking for smile correction. This case report describes the conventional and innovative approach of smile designing using an acrylic guide for correcting dimensions of teeth and gingival zenith position. Gingival pigmentation was also corrected to obtain esthetically pleasing gingival. Proper mock-up of diagnostic cast following all the rules of esthetics was done to visualize the final outcome. With introduction of veneers, conservative tooth preparation with high esthetics gain has become popular for management of unesthetic teeth.

© This is an open access article distributed under the terms of the Creative Commons Attribution License (<https://creativecommons.org/licenses/by/4.0/>) which permits unrestricted use, distribution, and reproduction in any medium, provided the original author and source are credited.

1. Introduction

The crafting of ideal smile requires analysis and evaluations of the face, lips, gingival tissues, and teeth and an appreciation of how they appear collectively. Such an ideal smile depends on the symmetry and balance of the facial and dental features,¹ keeping all principles of esthetics in mind, the case with unpleasant smile due to unesthetic form, texture and shade of teeth is managed with veneers along with maintaining gingival esthetics by correcting zenith position and gingival depigmentation. A simple innovative approach is used for smile designing in the case.²

2. Case Report

A 20 year old female reported to the OPD of Prosthodontics, Crown and bridge with chief complain of poor esthetics

because of stained and irregular upper and lower front teeth. She also complained about dark colored gingiva around tooth. Intra oral examination revealed moderate fluorosis with wide band of deeply pigmented gingiva in anterior tooth. After visual assessment and periodontal probing, gingiva was found to be of thick biotype. Gingival zenith position was not in harmony with the dental sub structures and was unaesthetic. Esthetic assessment of tooth showed pitted enamel, and irregular tooth surface. During smile only maxillary teeth were visible. After clinical evaluation, the treatment plan includes gingival depigmentation along with zenith correction followed by placement of E-max veneers.

2.1. Wax-up and Splint fabrication

Preliminary impressions were taken in irreversible hydrocolloid and cast were poured in dental stone type III (Figure 1). Diagnostic wax up was done to visualize future gingival margins with correct zenith position in accordance

* Corresponding author.

E-mail address: drabhishek.gupta1994@gmail.com (A. K. Gupta).

to the principles of esthetics (Figure 2). The diagnostic cast with mock-up was duplicated in dental stone type III. On this master cast splint sheet was adapted (Figure 3). Splint sheet was cut corresponding to corrected gingival margins. It would act as a guide during zenith correction.

2.2. Gingival correction

Splint sheet was adapted intra-orally. The margins were marked with eosin pencil (Figure 4). After splint removal, gingival margins were incised corresponding to marked markings using Nd-YAG laser (Figure 5). After zenith correction, depigmentation of gingiva was done using 15 number blade (Figure 6). Gingival packing was done for one week to facilitate healing.

2.3. Correction of teeth disharmony

After one week of healing, Perio pack was removed. After assessing gingival healing, tooth preparation was carried out to correct size, shape and surface of fluorosed tooth. The principles of tooth preparation for veneers was followed. After 0.5-1mm facial reduction incisal overlap margins were chosen because it provides a vertical stop for seating veneers (Figure 7). The finish lines were kept 1 mm away from centric contacts.

After gingival retraction, impression was made in polyvinyl siloxane by putty-wash technique. The shade selection was done under direct sunlight with Vita 3d master shade guide. Temporization was done using indirect method with application of light cure composite resin.

2.4. Veneers cementation

The temporary veneers were removed, the teeth were cleaned with pumice and air dried. The E-max veneers were tried on tooth with try-in paste to verify fit and esthetics. When the patient was satisfied with esthetics and shape of veneer, they were removed and cleaned under running water.

Veneers were air dried prior to final cementation (Figure 8). The cementation was done using Rely-X Calibra resin cement under manufacturer's instructions. Occlusion was checked to ensure no contact existed on tooth-porcelain junction interface.

The patient was satisfied with her smile. Post cementation instructions were given to the patient. Regular follow up was done at 2 weeks and 4 weeks interval to assess oral hygiene status. After 2 months, recall at interval of 3 months for initial 1 year followed by check-up at every 6 months was advised.

3. Discussion

In this era, where looks hold the key to success and confidence, smile designing has emerged as a powerful tool for patients with facial or dental discrepancies. Factors

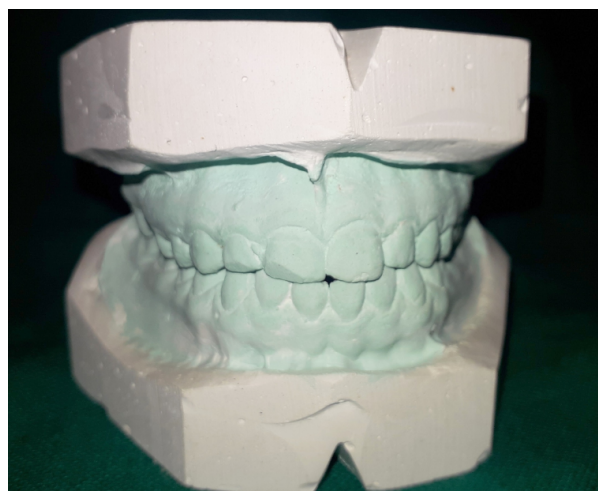

Fig. 1: Diagnostic Cast.

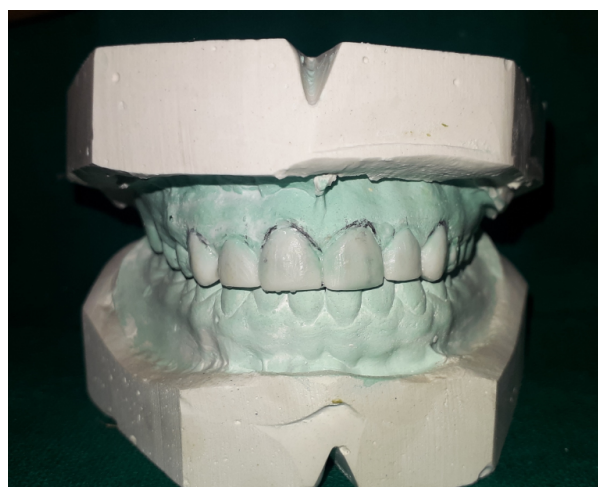

Fig. 2: Wax up done on diagnostic cast.

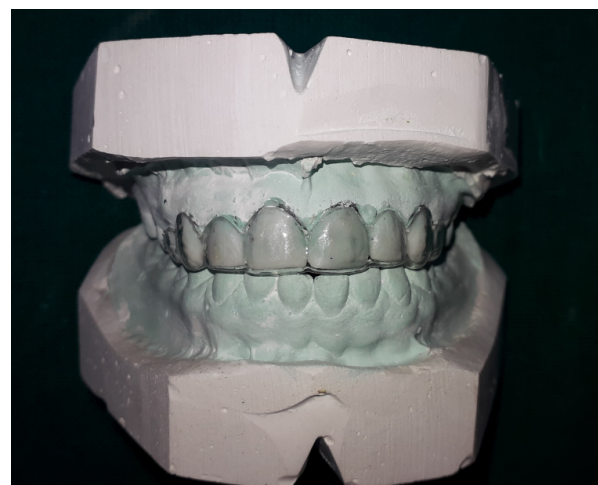

Fig. 3: Splint sheet adapted on waxed up cast.

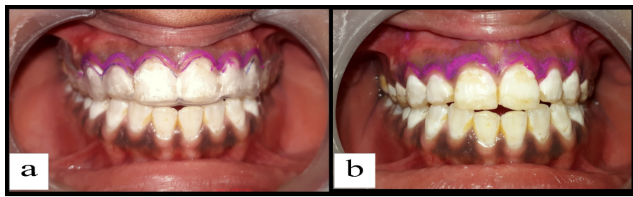


Fig. 4: (a) Splint placed intra-orally. (b) Margins marked with eosin pencil.

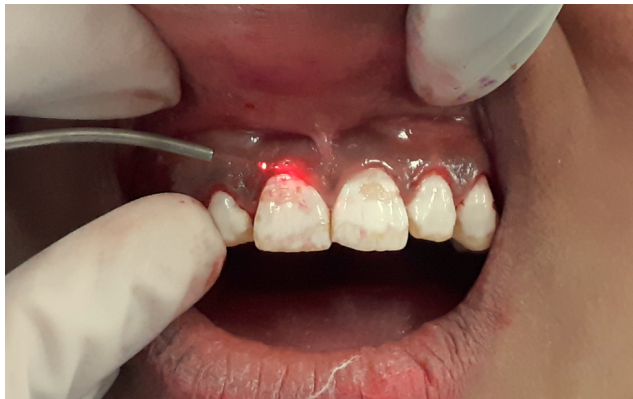

Fig. 5: Zenith correction done via Nd: YAG laser.

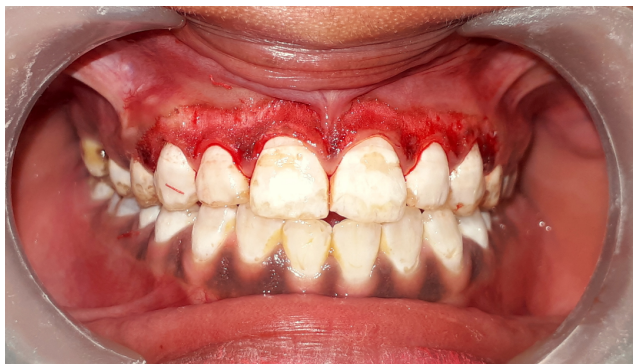

Fig. 6: Gingival depigmentation done.

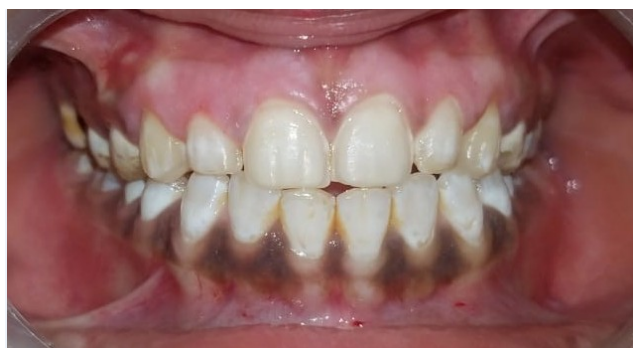

Fig. 7: Tooth prep done after healing of gingival tissues.

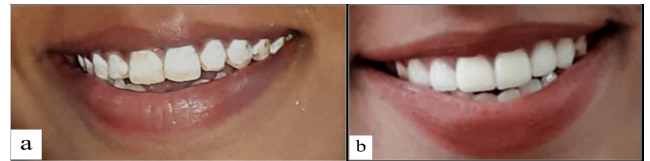


Fig. 8: (a) Pre rehabilitation view. (b) Post rehabilitation view.

determining dental composition can be categorized as tooth related and soft tissue related.¹ tooth related components includes incisal length, tooth dimensions, dental midline, zenith points, interdental contacts area, inclination of teeth, symmetry whereas soft tissue related components includes gingival health, colour, gingival level and harmony, interdental embrasure and smile line. As clinicians it is important to conduct systemic examination of all of determining factors of smile. In literature, there are various methods are given for evaluation and correction of smile including smile designing in case of discoloured teeth, management of case with high smile line where more gums are visible which looks unpleasant to many of patients. For management of any kind of case, it is important to properly diagnose and do preliminary mockup to visualize the future outcome of restoration and it can help the patient to be able to visualize future result. As digitization is overpowering the conventional methods in many aspects, smile designing has also become more systemically and predictable using digital smile designing (DSD).^{3,4} It helps in evaluating the harmony between teeth and gingival portion along with facial structures. DSD being costly and need for special software makes it difficult to be used by every clinicians and in every cases. As an alternative to DSD Conventionally done proper wax up can be done in keeping thorough knowledge of all the aspects of teeth and gingival display. In the present case report, properly done waxed up was utilized to make a transparent splint adapted on duplicated cast of waxed up diagnostic model. This splint was used introrally to accurately guide and locate for amount of gingivectomy required for zenith correction. It was done using laser surgery. As patients was having dark pigmented gingiva, it was also surgically depigmented using scalpel. Splint also guided in amount of tooth reduction needed for restoration and also in provisionalization.

Teeth proportion and colour were corrected with minimally invasive method, using veneers. Principles of tooth preparation for veneer was strictly followed. So following this simple and innovative approach, we can do smile correction.

4. Conclusion

Oral aesthetic rehabilitation is achieved by restoring gingival contour with dental harmony. Gingival architecture harmony seems to be a fundamental component of an

esthetic smile. It is followed by a prosthetic treatment in harmony with the healthy surrounding tissues. All the factors should be considered while deciding the treatment plan for such patients. A successful 1-year follow-up was done in the current clinical situation which has proved satisfactorily.

5. Declaration of patient consent

The authors certify that they have obtained all appropriate patient consent forms. In the form the patient(s) has/have given his/her/their consent for his/her/their images and other clinical information to be reported in the journal. The patients understand that their names and initials will not be published and due efforts will be made to conceal their identity, but anonymity cannot be guaranteed.

6. Source of Funding

None.

7. Conflicts of interest

There are no conflicts of interest.

References

1. Bhuvaneshwaran M. Principles of smile design. *J Conserv Dent.* 2010;13(4):225–32. doi:10.4103/0972-0707.73387.
2. Coachman C, Paravina RD. Digitally Enhanced Esthetic Dentistry - From Treatment Planning to Quality Control. *J Esthet Restor Dent.* 2016;28(1):S3–S4. doi:10.1111/jerd.12205.
3. Sancho-Puchades M, Fehmer V, Hämmerle C, Sailer I. Advanced smile diagnostics using CAD/CAM mock-ups. *Int J Esthet Dent.* 2015;10:374–91.
4. Cattoni F, Mastrangelo F, Gherlone EF, Gastaldi G. A New Total Digital Smile Planning Technique (3D-DSP) to Fabricate CAD-CAM Mockups for Esthetic Crowns and Veneers. *Int J Dent.* 2016;2016:1–5. doi:10.1155/2016/6282587.

Author biography

Mamta Kumari, MDS Graduate

Abhishek Kumar Gupta, 3rd year Post Graduate Student

Rekha Gupta, HOD

Cite this article: Kumari M, Gupta AK, Gupta R. Rejuvenating the smile with dental and gingival harmony- A case report. *IP Ann Prosthodont Restor Dent* 2020;6(4):220-223.