



## Case Report

# Fabrication of a customised hader bar using a coffee stirrer for tooth supported overdenture - A case report

Swapnil Chincholikar<sup>1,\*</sup>, Rohit Prasad<sup>2</sup>, Aarti Goel<sup>3</sup>, Sonal Saumya<sup>4</sup>

<sup>1</sup>Dept. of Prosthodontics, Celebrity Smiles Dental Clinics, Bangalore, Karnataka, India

<sup>2</sup>Dept of Periodontology, Faculty of Dental Science, Ramaiah University of Applied Sciences, Bangalore, Karnataka, India

<sup>3</sup>Dept. of Endodontics, Clove Dental, Bangalore, Karnataka, India

<sup>4</sup>Dept. of Prosthodontics, Celebrity Smiles Dental Clinics, Bangalore, Karnataka, India



## ARTICLE INFO

### Article history:

Received 05-09-2020

Accepted 19-09-2020

Available online 02-11-2020

### Keywords:

Customized Hader Bar

Tooth supported overdenture

Cast copings

Bar supported overdenture

## ABSTRACT

The concept of Preventive Prosthodontics utilising conventional tooth-retained overdentures is a simple and cost effective treatment compared to implant overdentures. The concept of tooth supported overdentures is getting less popular because of advent of implant supported overdentures/hybrid dentures, but it is still utilised and provides a satisfactory means of rehabilitation and helps in delaying the process of residual ridge resorption and thus, helps in the preservation of bone, especially in patients who cant afford and/or cant undergo implant surgery because of health issues. A number of attachment systems are available for tooth supported overdenture treatment modality. The objective of all the systems is to provide retention and support for the overdenture, but the bar retained systems are expensive. This case report describes a simple and economic way of fabrication of a customised Hader bar using a simple coffee stirrer for tooth supported overdenture.

© This is an open access article distributed under the terms of the Creative Commons Attribution License (<https://creativecommons.org/licenses/by/4.0/>) which permits unrestricted use, distribution, and reproduction in any medium, provided the original author and source are credited.

## 1. Introduction

A terminal dentition patient requiring multiple teeth extractions and conventional/tooth supported/implant supported complete denture goes through a sequel of events like loss of tooth proprioception, progressive loss of alveolar bone, transfer of all occlusal forces from the teeth to the oral mucosa and loss of patient's self-confidence.

The statement by Muller DeVan "Perpetual preservation of what remains is more important than the meticulous replacement of what is missing" still remains the gold standard. Preventive prosthodontics emphasizes the importance of any procedure that can delay or eliminate future prosthodontic problems and overdenture is an important part of the preventive treatment modality.<sup>1,2</sup>

Overdenture is any removable dental prosthesis that covers and rests on one or more remaining natural teeth, the roots of natural teeth and/or dental implants (GPT-8).<sup>3</sup> They provide a better function than conventional complete dentures through a variety of factors, such as improved biting force, chewing efficiency and increased speed of controlled mandibular movement.<sup>4</sup> In addition, they minimize the downward and forward settling of a denture, which otherwise occurs with alveolar bone resorption, thus reducing the rate of residual ridge resorption.<sup>5</sup>

The various attachments systems such as the Dolder bar (Dolder Bar System; Attachments Intl, Inc, Burlingame, Calif) and the Hader bar (Hader-EDS Bar System; Attachments Intl, Inc) are the most commonly used attachments for overdentures and implant retained restorations.<sup>6,7</sup> But these attachment bar systems are expensive.

This case report describes an economical tooth-supported overdenture with customized castable Hader bar

\* Corresponding author.

E-mail address: [swapnil.chincholikar@gmail.com](mailto:swapnil.chincholikar@gmail.com) (S. Chincholikar).

metal superstructure fabricated with a coffee stirrer stick attached to the lower denture and it incorporates the use of plastic retention clip inside a metal superstructure, which gives the added advantage of plastic clip removal and replacement with new clip after wear or loosening of the existing clip.<sup>8</sup> Studies have shown that amongst the various bar attachment systems the Hader bar produced less torquing force and that the force distribution between the posterior edentulous area and the contralateral abutments was better in comparison with the other systems.<sup>9</sup>

## 2. Case Report

A 60-year-old female patient reported to the Department of Prosthodontics with the chief complaint of difficulty in chewing food. The maxillary arch was completely edentulous and the mandibular arch was partially edentulous for the past 7-8 months. The patient was diabetic from the past 10 years and had a mixed diet.

Intraoral examination showed completely edentulous maxillary and partially edentulous mandibular arches with firm canines (33, 43). The patient did not want her remaining teeth to be extracted. Keeping in mind the patient's desires and treatment needs, it was decided not to extract these teeth. Oral prophylaxis was carried out for the remaining teeth and diagnostic models were mounted on a semi-adjustable articulator (for tentative jaw relations). This was performed to assess the interocclusal space, and it was found to be adequate and satisfactory.

On the basis of this assessment the treatment plan formulated was, to fabricate a single complete denture for maxillary edentulous arch and bar attachment supported overdenture for partially edentulous mandibular arch.

The other treatment options that were presented to the patient were, extraction of the remaining teeth followed by conventional complete denture in upper and lower arch and extraction followed by implant-supported overdenture in lower arch and conventional complete denture in upper arch.

The completely edentulous maxillary arch [Figure 1] and partially edentulous mandibular arch [Figure 2] was evaluated for presence of any sharp bony spicule or undercut. Intentional root canal therapy was carried out for the mandibular canine teeth (33 and 43). Tooth preparation was carried out on both the teeth and chamfer finish line was given. Intracoronal post space preparation was done so as to have extensions of the bar in the tooth structure.

Impression of the prepared teeth [Figure 3] was taken with putty and light body impression material (Reprosil<sup>®</sup> Hydrophilic Vinyl Polysiloxane, DENTSPLY Caulk) and Die stone (type IV dental stone), (Kalstone; Kalabhai) was poured and model was made. Inlay casting wax (Renfert; Germany) was used to fabricate copings on the mandibular canine teeth and the metal housing for the retentive sleeve [Figure 4]. The two wax copings on the mandibular canine

teeth were connected with a Plastic Coffee stirrer stick (Café Coffee Day, India) of 2 mm thickness and 3 mm height. The wax patterns for the bar-coping assemble and the housing were invested and cast in a Ni-Cr alloy (Nickel-chromium alloy (Super Cast)) using standard technique [Figure 5]. The castings thus obtained were finished and highly polished to avoid any rough areas which lead to plaque accumulation. The metal bar with retainer copings were tried first on the cast and then intraorally to check for the passive fit of the same. [Figure 6]

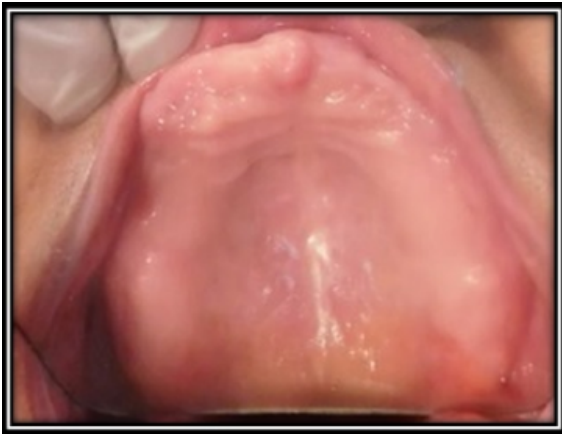The bar, along with the metal copings, was luted onto the respective tooth preparations with the help of Resin cement (Rely X U200, 3M ESPE). Border moulding was done using a custom acrylic tray (DPI RR Cold Cure, India) with Monophase impression material (3M ESPE Monophase Polyether) and the secondary impression was made using Polyether impression material (3M ESPE Impregum soft) [Figure 7]. The remaining steps up to try-in were carried out in the conventional manner for complete denture.

On the day of prosthesis delivery, the yellow medium retention plastic clip and the metal housing were secured over the bar. The mandibular denture was positioned over the housing and the spot was marked and cut using acrylic trimming burs to house the plastic clip and the metal housing. The undercut of the bar was then blocked with modelling wax. Cold cure acrylic (DPI RR Cold Cure, India) was mixed and in dough stage was placed in the intaglio surface of the denture in the trimmed area. Vaseline was applied on the bar and on the blocked out region. The mandibular denture was then placed in the mouth followed by the maxillary denture and the patient was asked to close in centric relation. After 5 minutes the denture was retrieved along with the metal housing and retention clip picked up in the denture. Excess acrylic was trimmed and the intaglio surface was polished using burs and sand paper. [Figure 8]

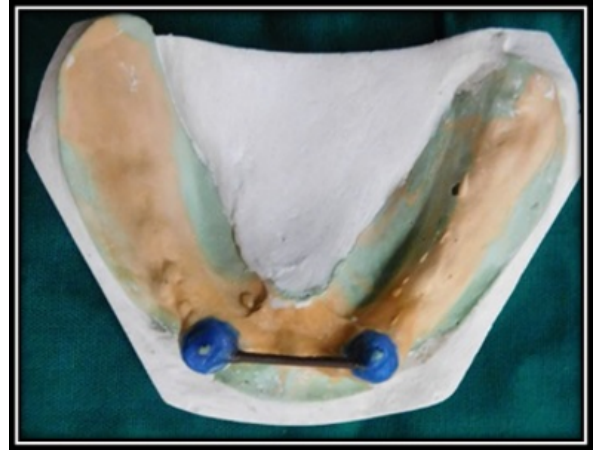The patient was trained for insertion and removal of the denture and post insertion instructions were given. The maintenance and importance of denture hygiene was explained and demonstrated in detail. Post insertion follow up visits were done at 1 day, 3 days and 7 days. The patient was satisfied with the amount of retention and stability.

## 3. Discussion

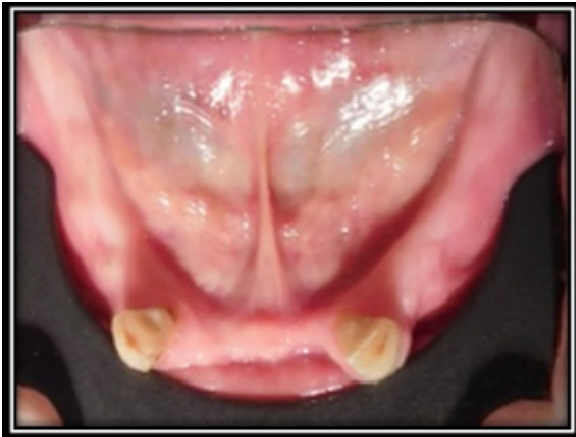As the popularity of Implant dentistry has increased in the rehabilitation of missing teeth, tooth supported overdentures have taken a backseat. Still the modality remains the treatment of choice for those patients who cannot afford the costs associated with implant surgery and/or are medically unfit to undergo the same. The overdenture treatment modality is basically a "preventive prosthodontic concept", Prothero in 1916; stated, "Oftentimes two or three widely separated roots or teeth can be utilized for supporting a denture."<sup>10</sup>



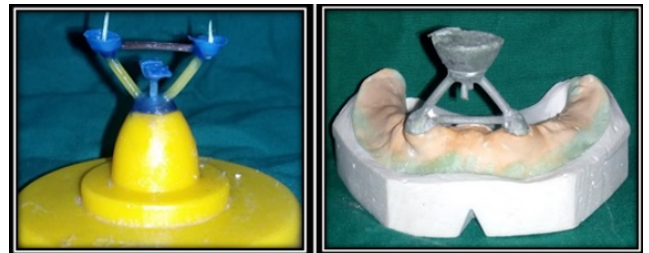
**Fig. 1:** Pre Op Maxillary arch (Intraoral)



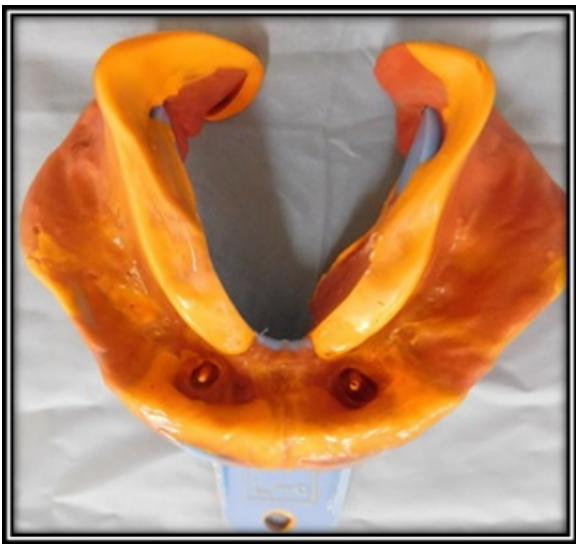**Fig. 4:** Inlay wax pattern for customised bar



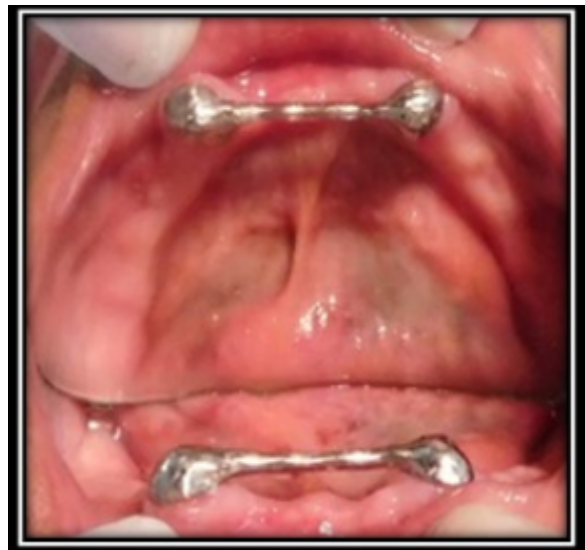**Fig. 2:** Pre Op Mandibular (Intraoral)



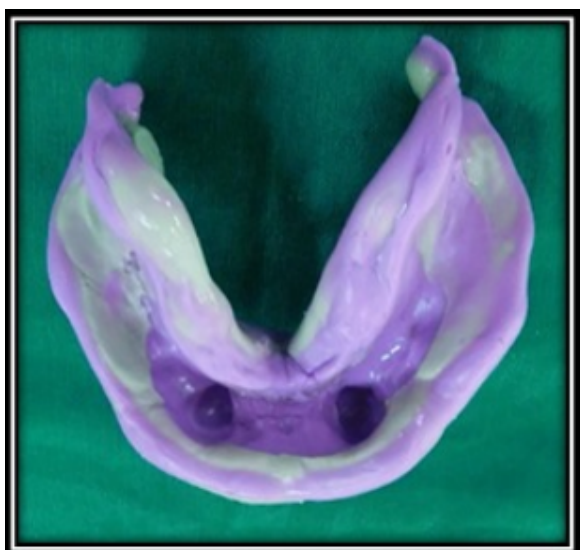**Fig. 5:** Invested wax pattern and retrieved Casting on master cast



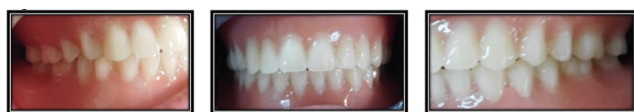**Fig. 3:** Abutment teeth impression



**Fig. 6:** Copings and Metal bar try-in (Intraoral)



**Fig. 7:** Final impression



**Fig. 8:** Denture insertion

The teeth which are considered otherwise hopeless for routine restorative procedures can be successfully used as overdenture abutments. The mandibular ridge resorbs almost four times faster than the maxillary ridge according to the literature.<sup>11,12</sup> It is also proven that the bone/supporting structures around the retained teeth or implants are maintained for a longer duration of time, thus, resulting in slower rate of residual ridge resorption and increased stability and retention of the denture.<sup>12</sup>

Overdentures require a very careful assessment of the available vertical space. There must be sufficient vertical room for overdenture copings and attachments, together with an adequate thickness of denture base material and artificial teeth, so that the strength of the denture is not compromised.<sup>13</sup> Overdenture with attachments can redirect the occlusal forces away from the weak supporting abutment teeth and onto a soft tissue or redirect them toward stronger abutments thereby resulting in superior retention.<sup>14</sup> The use of stress breakers is always advisable whenever the load is expected to jeopardize the existing condition of the abutment teeth. The bar attachment offers slight vertical and rotational movement of the denture as well as a stress breaker action. Bar exhibits more cross-arch involvement and allows occlusal forces to be shared between the abutments.<sup>15</sup>

#### 4. Conclusion

The use of two canines as abutments splinted together with a bar is more advantageous than using the individual

abutments separately. This is due to the splinting effect of the bar. Thus to conclude, mandibular tooth-supported overdenture with a customised bar attachment using a coffee stirrer provides an economical solution of rehabilitation of edentulous patients and fulfills the objectives of retention, stability, support and esthetics.

#### 5. Source of Funding

No financial support was received for the work within this manuscript.

#### 6. Conflict of Interest

The authors declare they have no conflict of interest.

#### References

- Morrow RM, Feldmann EE, Rudd KD, Trovillion HM. Tooth-supported complete dentures: An approach to preventive prosthodontics. *J Prosthetic Dent.* 1969;21(5):513–22. doi:10.1016/0022-3913(69)90073-0.
- Dodge CA. Prevention of complete denture problems by use of “overdentures”. *J Prosthetic Dent.* 1973;30(4):403–6. doi:10.1016/0022-3913(73)90161-3.
- The glossary of prosthodontic terms (GPT 8); 2005.
- Rissin L, House JE, Manly RS, Kapur KK. Clinical comparison of masticatory performance and electromyographic activity of patients with complete dentures, overdentures, and natural teeth. *J Prosthetic Dent.* 1978;39(5):508–11. doi:10.1016/s0022-3913(78)80181-4.
- Crum RJ, Rooney GE. Alveolar bone loss in overdentures: A 5-year study. *J Prosthetic Dent.* 1978;40(6):610–3. doi:10.1016/0022-3913(78)90054-9.
- Preiskel HW. Precision attachments in prosthodontics: overdentures and telescopic prostheses. Chicago: Quintessence; 1984.
- Dolder EJ. The bar joint mandibular denture. *J Prosthet Dent.* 1961;11(4):689–707. doi:10.1016/0022-3913(61)90178-0.
- Guttal SS, Nadiger RK. Use of coffee straw for overdenture bar fabrication. *J Prosthetic Dent.* 2009;102(4):266. doi:10.1016/s0022-3913(09)60170-0.
- Thayer HH, Caputo AA. Photoelastic stress analysis of overdenture attachments. *J Prosthetic Dent.* 1980;43(6):611–7. doi:10.1016/0022-3913(80)90374-1.
- Prothero JH. Prosthetic dentistry. Chicago: Medico Dental Publishing Company; 1916. p. 519.
- Tallgren A. The continuing reduction of the residual alveolar ridges in complete denture wearers: A mixed-longitudinal study covering 25 years. *J Prosthet Dent.* 1972;27(2):120–32. doi:10.1016/0022-3913(72)90188-6.
- Crum RJ, Rooney GE. Alveolar bone loss in overdentures: A 5-year study. *J Prosthetic Dent.* 1978;40(6):610–3. doi:10.1016/0022-3913(78)90054-9.
- Dolder EJ. The bar joint mandibular denture. *J Prosthetic Dent.* 1961;11(4):689–707. doi:10.1016/0022-3913(61)90178-0.
- Bambara GE. The attachment-retained overdenture. *NY State Dent J.* 2004;70:30–3.
- Williamson RT. Retentive bar overdenture fabrication with preformed castable components: A case report. *Quintessence Int.* 1994;25(3):89–94.

#### Author biography

Swapnil Chincholikar, Consultant Prosthodontist

**Rohit Prasad**, Assistant Professor

**Aarti Goel**, Consultant Endodontist

**Sonal Saumya**, Consultant Prosthodontist

**Cite this article:** Chincholikar S, Prasad R, Goel A, Saumya S. Fabrication of a customised hader bar using a coffee stirrer for tooth supported overdenture - A case report. *IP Ann Prosthodont Restor Dent* 2020;6(4):211-215.