



Case Report

Innovative technique to enhance the art of oculistry: A case report

Harmanpreet Atwal^{1,*}, Tanuj Mendiratta¹, Dinesh Kumar¹, Rajesh Kumar Yadav¹,
Amit Khattak¹

¹Dept. of Prosthodontics and Crown & Bridge, Army Dental Centre (Research & Referral), New Delhi, India



ARTICLE INFO

Article history:

Received 09-09-2020

Accepted 19-09-2020

Available online 24-09-2020

Keywords:

Custom ocular prosthesis

Gaze fixation

Iris selection

NAES ruler

ABSTRACT

Loss of any organ of a body is a traumatising event as it creates functional, esthetics and psychological disharmony in an individual's life. An ocular defect can be a congenital anomaly or an acquired defect. Rehabilitation of such defect with customized well fitting prosthesis that restores the shape of associated anatomical structures and volume of the socket, not only require an artistic skill but also technical knowledge as every case is unique on its own. The main objective of this article is to describe innovative yet simple technique using NAES ruler for iris selection and fixation of gaze yielding results with utmost patient satisfaction and acceptance.

© 2020 Published by Innovative Publication. This is an open access article under the CC BY-NC license (<https://creativecommons.org/licenses/by-nc/4.0/>)

1. Introduction

Eyes are the window to the soul and an epitome of cosmetic appearance in human beings. Anophthalmia can be the result of congenital defect, tumors or trauma. The removal of globe of the eye may be done by evisceration, enucleation or exenteration.¹ Ocular prosthesis has been used since centuries to provide cosmetic replacement for enucleated and eviscerated eyes.² Trauma is considered the leading cause of an eye loss. Spraul and Grossniklaus reported that the main cause of enucleation is trauma in 41% of cases and neoplasia in 24% of cases³ with other factors being corneal disease, blind painful eye, glaucoma and post operative complications.

For an ideal ocular prosthesis fabrication various challenges of ptosis, socket contraction, correct selection and orientation of iris along with sagging of surrounding tissues have to be overcome to make the prosthesis look natural with adequate palpebral opening, scleral visibility, matching iris shade and size to that of the contralateral eye.¹ This not only enhances the esthetics and overall facial harmony but also makes the eye movements smooth,

increases patient's comfort and restores the tissue to their original size and contour giving the prosthesis a more natural appearance.⁴

Various materials have been used to fabricate ocular prosthesis ranging from glass eyes in the past to stock eyes, modification of stock eyes, custom ocular prosthesis fabrication⁵ and to nowadays making 3-D printing of scleral shell a reality.⁶ This case report highlights the fabrication of a customized ocular prosthesis using a NAES ruler for correct selection of iris size followed by its accurate orientation giving a natural conversational gaze to the patient. This simple yet innovative technique can be used routinely as it yields good results and also reduces chairside time.

2. Case Report

A 28 years old male patient was referred to our Department of Prosthodontics and Crown & Bridge from an Ophthalmologist. The patient complained of defect of right eye caused by accidental traumatic injury about a year back and desired for prosthetic rehabilitation of the same [Figure 1a]. On elicitation of history it was found that the patient was suffering from phthisis bulbi due to traumatic

* Corresponding author.

E-mail address: prettyatwal@gmail.com (H. Atwal).

injury and was spectacles to compensate for the same. The patient was emotionally traumatised and conscious of his appearance thus, was seeking for an esthetic rehabilitation of the defect. On examination, the shrunken defect was observed to be completely healed with phthisical globe having corneal opacity and normal sclera without any residual vision [Figure 1b]. A customized ocular prosthesis was planned for the patient and the formulated treatment was explained to the patient for his consent.

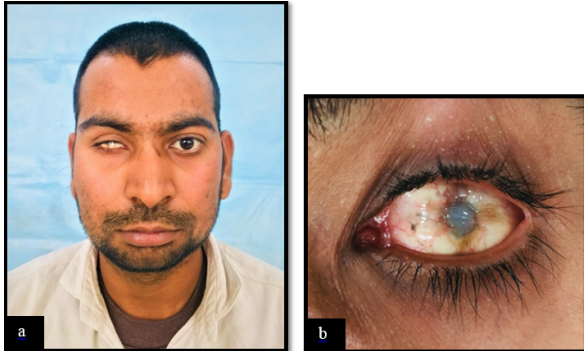

Fig. 1: Phthisical right eye

2.1. Impression making

The defect site was prepared by applying vaseline to the eyelashes and surrounding area to prevent sticking of the impression material. A custom ocular tray was fabricated by using the contour of stock eye with autopolymerising polymethylmethacrylate resin (DPI, India) [Figure 2a]. To the centre of the tray a handle, made by perforating head of the cap of a disposable syringe, was attached for easy and continuous flow of the impression material. After finishing of the tray, it was checked for the extensions in the patient's eye. A universal tray adhesive (Coltene, India) was applied to the tray and allowed to dry for 10 mins [Figure 2b]. An impression of the defect was made by injecting slowly light body consistency addition silicone elastomeric impression material (Virtual, Light body, Ivoclar Vivadent, India) through the head of the custom ocular tray. The patient was asked to look forward during the impression making and asked to close his eyes slowly so that the excess material flows out through the perforations of the tray. On setting the impression was retrieved carefully [Figure 2c] and evaluated for any defect.

2.2. Fabrication of wax pattern & trial

Sectional indexed putty mould of the impression was made using putty consistency addition silicone (Virtual, Putty, Ivoclar Vivadent, India) [Figure 3a] which was used to fabricate wax pattern by pooling molten wax (DPI, India) in the index. The retrieved pattern was contoured and finished before trial in the patient [Figure 3b]. The patient was

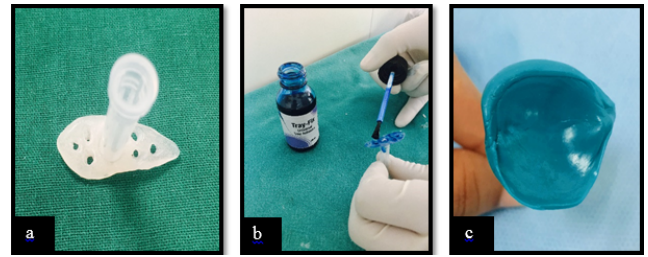


Fig. 2: Impression making

asked to sit upright during the trial and perform all the eye movements [Figure 4]. Necessary modification of the pattern was done till satisfactory eyelids contour, smooth eye movements along with comfortable opening and closing action of the eyelids was achieved.

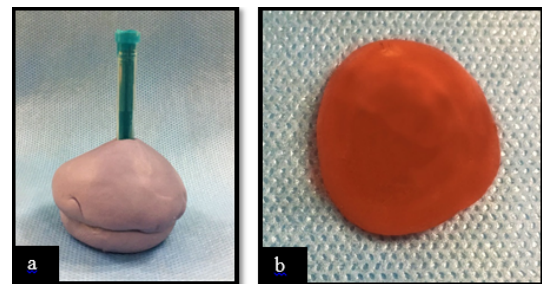


Fig. 3: Wax pattern fabrication



Fig. 4: Eye movements during wax pattern trial

2.3. Iris selection and fixation of gaze using NAES ruler

Once patient's approval of the scleral wax pattern in terms of function and comfort was taken then, the iris positioning was done using NAES ruler.

NAES ruler: This plastic flexible ruler consists of nasal bridge notch and two eye boxes on either side of the notch. These boxes are equidistant from the centre of the nasal bridge notch. The marking of 30 in each box creates a distance of 60mm as the interpupillary distance. The average value of interpupillary distance observed in Indian population is approximately 46-70mm in males and 46-75mm in females.⁷ It also has dimensions of iris and pupil

size on the other side of the ruler which aids in the selection of the iris appropriate for a particular patient [Figure 5a].

First, using the ruler the iris size of contralateral eye of the patient was measured which was 11.5mm in diameter [Figure 5b]. It was followed by positioning the centre of iris on the pattern by using the eye boxes on either side which aided in superoinferior and mediolateral orientation of the iris [Figure 5c]. The centre of the iris was marked on the pattern and using it as the centre a circle was drawn with diameter of 11.5mm depicting the tentative location of the iris on the pattern [Figure 5d].




Fig. 5: Iris selection & fixation of gaze using NAES ruler

2.4. Fixing the aluminium disc

The marked location of iris was fixed with the help of an appropriate size of aluminium button which was oriented while maintaining the patient in a conversational gaze. The stock of the aluminium button gave a precise outcome of the orientation of the button while the patient looked forward. Minor adjustments in orientation of the button was done conveniently without removing it every time by heating the stock of the button and giving it the required tilt, until a satisfactory centring of iris with gaze fixation was achieved [Figure 6a].

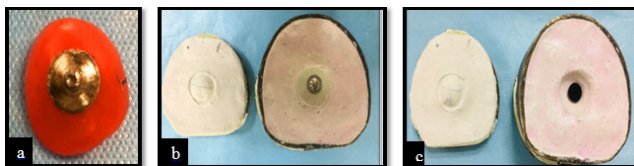


Fig. 6: Aluminium button fixation & processing

2.5. Acrylization of the scleral shell

The finished wax pattern with aluminium button in place was then invested in a flask which was followed by dewaxing. Post dewaxing the stock of the aluminium button which was embedded in the plaster [Figure 6b] was carefully removed and replaced with corneal button of same size for curing [Figure 6c]. Acrylization was done following manufacturer's instructions using medical grade

heat polymerized clear polymethylmethacrylate (Factor II, Lakeside, USA) to which stains were added to obtain necessary scleral shade. Long curing cycle was followed to reduce residual monomer content.

2.6. Characterisation

The retrieved prosthesis was finished and reduced about 1mm for clear acrylic resin [Figure 7 a]. It was followed by scleral painting by using freshly prepared monopoly syrup to mimic the sclera of the contralateral eye. Veining fibres were adhered to the shell using the same syrup giving it a natural appearance [Figure 7b]. The prosthesis was then repositioned in the same flask, packed with medical grade heat polymerized clear polymethylmethacrylate (Factor II, Lakeside, USA) and cured following long curing cycle. The retrieved prosthesis was inspected for any imperfections, finished and polished to get a glass like finish [Figure 7c].

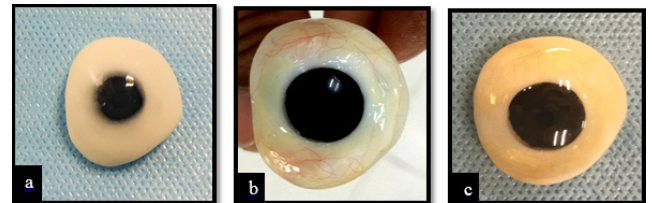


Fig. 7: Acrylized prosthesis, characterization & finished prosthesis

2.7. Insertion and instructions

The prosthesis was inserted in situ after washing with mild soap water and evaluated for lid drape, contour, comfort and function [Figure 8]. The patient appeared to be contented with his new appearance and was recalled for periodic follow up. The result showed a successful, time saving, and natural looking rehabilitation of the ocular defect. The do's and don'ts were explained and patient's instructions perform was handed over to the patient for convenience.



Fig. 8: Post op result

3. Discussion

One of the pioneers in field of Ocularistry was Ambriose Pare from France (1510-1590).⁸ He fabricated eyes made of glass and porcelain. Since then it has been under a continuous process of evolution. Various materials, techniques and technologies have been devised which are cost and time effective and aim for results with high patient satisfaction.^{9,10} Selection of iris color and size along with fixation of gaze is the most critical step in successful rehabilitation of an ocular defect. The method described here is using the NAES ruler. With this multipurpose ruler measurements of iris and interpupillary distance can easily be made due to it's flexibility. It is not cumbersome like other methods and is user friendly giving multiple different readings on a single ruler.

The aluminium button used in this technique is available in various sizes of small, medium and large. Depending upon the iris size suitable aluminium button suitable for the patient is selected and used. The corneal button also should correspondingly match the selected aluminium button size before its replaced in the flask to get the desired result. The convenience of adjusting the button without repeatedly removing it makes it simple and easy to use.

4. Conclusion

The method described here is simple, economical and time efficient. Incorporation of this technique reduces the chances of errors and gives results with more predictable clinical outcome and pleasing esthetics.

5. Declaration of Patient Consent

The authors certify that they have obtained appropriate patient consent forms. The patient has given his consent for the images and other clinical information. The patient understands that his name and initials will not be published and due efforts will be made to conceal his identity, but anonymity cannot be guaranteed.

6. Source of Funding

None.

7. Conflict of Interest

None.

References

1. Beumer J, Marunick MT, Esposito SJ. Maxillofacial Rehabilitation Prosthodontic and Surgical Management of Cancer-Related, Acquired, and Congenital Defects of Head and Neck. USA: Quintessence Publishing Co, Inc.; p. 302–4.
2. Kale E, Meşe A, İzgi AD. A Technique for Fabrication of an Interim Ocular Prosthesis. *J Prosthodont*. 2008;17(8):654–61.
3. Spraul CW, Grossniklaus H. Analysis of 24,444 surgical specimens accessioned over 55 years in an ophthalmic pathology laboratory. *Int Ophthalmol*. 1997;21(5):283–304.
4. Bethke EG. Criteria and Guide for Evaluation of Ocular Prostheses. *Am J Ophthalmol*. 1952;35(4):527–36.
5. Bartlett SO, Moore DJ. Ocular prosthesis: A physiologic system. *J Prosthetic Dent*. 1973;29(4):450–9.
6. Ruiters S, Sun Y, d Jong S, Politis C, Mombaerts I. Computer-aided design and three-dimensional printing in the manufacturing of an ocular prosthesis. *Br J Ophthalmol*. 2016;100(7):879–81.
7. Gupta VP, Sodhi PK, Pandey RM. Normal values for inner intercanthal, interpupillary, and outer intercanthal distances in the Indian population. *Int J Clin Pract*. 2003;57(1):25–9.
8. Chalian VA, Drane JB, Standish SM. Maxillofacial Prosthetics: Multidisciplinary Practice. vol. 94. Baltimore: The Williams & Wilkins Co; 1971. p. 286–94.
9. Sajjad A. Ocular prosthesis-a simulation of human anatomy: a literature review. *Cureus*. 2012;6(12):1–14.
10. Brown KE. Fabrication of orbital prosthesis. *Plast Reconstr Surg*. 1970;24(5):225–35.

Author biography

Harmanpreet Atwal Resident

Tanuj Mendiratta Resident

Dinesh Kumar Senior Specialist

Rajesh Kumar Yadav Senior Specialist

Amit Khattak Senior Specialist

Cite this article: Atwal H, Mendiratta T, Kumar D, Yadav RK, Khattak A. Innovative technique to enhance the art of ocularistry: A case report. *IP Ann Prosthodont Restor Dent* 2020;6(3):176-179.