



Case Report

Prosthetic augmentation of sunken cheeks using hollow PVC pipe cheek plumpers – A case report

Aarti Mehta^{1,*}, Sunil Kumar MV¹, Harikesh Rao¹

¹Dept. of Prosthodontics, Jaipur Dental College, Jaipur, Rajasthan, India



ARTICLE INFO

Article history:

Received 26-07-2020

Accepted 29-07-2020

Available online 24-09-2020

Keywords:

Cheek plumper

Hollow denture

Complete denture

Sunken cheeks

Cheek augmentation

Geriatric dentistry

Geriatric esthetics

Light weight denture

ABSTRACT

Prosthetic rehabilitation of edentulous patient has an ultimate aim of restoring absolute oral functions and esthetics. Hollow and slumped cheeks in completely edentulous patients reduce their over-all facial appearance and make them look further old. To confront this esthetic challenge, cheek lifting appliance can be used. The article here, illustrates simple and non-invasive technique of fabrication of complete denture with hollow cheek plumpers using pvc pipes, as one unit and light-weighted prosthesis. These add support to the flaccid oro-facial musculature and elevate the facial esthetics while maintaining the retentive characteristics of the complete denture.

© 2020 Published by Innovative Publication. This is an open access article under the CC BY-NC license (<https://creativecommons.org/licenses/by-nc/4.0/>)

1. Introduction

Esthetics has become pre-eminently an important part in the field of dentistry. This is largely in response to negative social and psychological consequences that follow unattractive facial looks.¹ Therefore, while prosthetically rehabilitating any edentulous patients, missing teeth and facial esthetics are parallelly restored.²

Cheeks are usually the most prominent part of the face that are supported by the teeth, ridges and muscles, there by having a critical role to play in facial esthetics. However loss of molars, complete edentulism, age related loss of muscle tone, weight loss are certain factors leading to concavities and hollowing out of cheeks. This results in reduced or lost cheek fullness giving a slumpy and skinny appearance to the face and makes the patient look older leading to unfavourable socio-psychological effects.^{1,2}

Normally in complete edentulous patients, the lost facial form and contours are usually re-established by restoring

vertical jaw relation records and adequate contouring and extension of denture flange.³ Despite that, in geriatric patients with excessive loss of facial fullness and hollowed cheeks, an extra support to flaccid oro-facial muscles is required. This is achieved prosthetically using cheek plumpers with complete denture.⁴⁻⁶ Use of artificial prosthesis for different augmentation procedures have also been documented in various literatures of maxillofacial studies.⁷⁻⁹

Cheek plumpers are usually a single unit prosthesis, fabricated in premolar-molar region that acts like a sub-structure or buttress over which the cheeks are supported and prevented from collapsing.¹⁰ The major shortfall of this design is an increase in the over-all weight of the prosthesis due to addition of extra quantity of denture base resin that may lead to over loading of residual ridges and adversely affect the retentive property of denture.

To overcome this drawback, a weight reduction approach has been tried. This case report illustrates the use of PVC pipe for fabricating hollow cheek plumper prosthesis in a

* Corresponding author.

E-mail address: rt.mehta3.am@gmail.com (A. Mehta).

patient with maxillary complete edentulous arch and sunken cheeks.

2. Case Report

A 63-years old male patient reported to the department of prosthodontics at Jaipur Dental College, Jaipur, Rajasthan, wanting the replacement for his missing teeth. History revealed that he had lost his teeth over a period of 2-3 years due to the problems of periodontal origin. The patient's main concern was the restoration of his lost masticatory function and also insisted on restoring his lost facial fullness due to sunken cheeks. Intra-oral examination of the patient had revealed completely edentulous maxillary arch and partially edentulous mandibular arch with remaining posterior natural teeth. (Figures 1 and 2). While the extra oral examination showed flaccid and unsupported orofacial musculature resulting in slumped and sunken cheeks (Figure 3). The treatment plan was formulated in accordance with the patient's need. Complete denture with hollow cheek plumpers was planned for maxillary arch which would be fabricated using heat resistant PVC pipes (figure 4). This would help to augment the sunken cheeks by providing artificial support intra-orally and also reduce the overall weight of prosthesis (the gross weight of each PVC pipe used was 1.9 gm approx. depicted in Figure 4) that would otherwise be heavy due to the added weight from polymerised resin in cheek plumper region. For mandibular arch a removable partial denture (gingival prosthesis) was planned that replaced the missing natural teeth in anterior region while posteriorly it extended as gingival mask for prosthetic coverage of exposed roots due to gingival recession.

In this article the procedures performed during fabrication of maxillary complete denture with hollow cheek plumpers using PVC pipes have been illustrated.

The primary impression of maxillary arch was made using impression compound (Y-Dent, MDM Trading corporation, Delhi) followed by custom tray fabrication using self-polymerizing acrylic resin (DPI RR Cold Cure, DPI, Mumbai, India) on primary cast. Border moulding with low fusing impression compound (DPI Pinnacle, The Bombay Burmah Trading Corporation Limited, Mumbai, India) was done and final impression was made using zinc-oxide impression paste (Impression Paste, DPI, Mumbai, India). Jaw relations were recorded followed by the waxed-up denture try-in procedure for the first trial of occlusion and esthetics. There after modeling wax was softened and molded in a cylindrical shaped cheek plumpers which were then tempered and attached to a distobuccal flange region of maxillary trial denture on both sides. This was then tried in the patient's mouth and necessary cheek lip movements were made. Extra-orally the required cheek fullness and support was evaluated for facial esthetics. After the patient has accepted the desired changes in his facial appearance,

the waxed up denture with cheek plumpers was taken for laboratory procedures. Routine flasking and de-waxing was done. Heat resistant hollow PVC pipes of 4mm diameter were secured in the mould space created in the area of cheek plumpers using cold cure resin plugs which can fit into the plug holes of wax strip for orientation of PVC pipes and also used for obliterating the entry holes of the hollow pipes (Figures 5 and 6). The assembly is set as shown in the Figure 7 and wax strip is carefully removed before the final packing. The self cure orientation plugs prevent the pipe's surface to come in direct contact with the periphery of mold space. This clearance helps the heat cure acrylic resin to completely surround the external surface of hollow pipe without exposing it out to the cameo surface of the denture. Final packing was done using heat-polymerising acrylic resin (DPI, Mumbai, India) and the denture was finished and polished. The final prosthesis was then checked for any discomfort, loss of function, esthetics in patient's mouth before denture delivery. (Figures 8 and 9)

The patient was educated about the prosthesis and trained for easy insertion and removal of the same. After assuring that the patient's needs have been met, the prosthesis was delivered and he was recalled for subsequent regular check-ups to assess and attend to any discomforts due to dentures.

Figure 10 depicts final result showing augmented cheek musculature in patient after prosthesis insertion and a drastic change in patient's over-all appearance can be appreciated which otherwise looked more senile and slumped in pre-operative phase depicted by Figure 3.

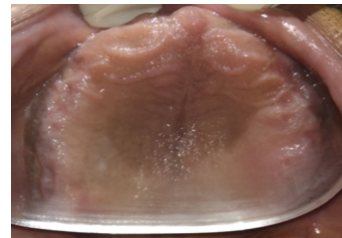


Fig. 1: Maxillary complete edentulous arch

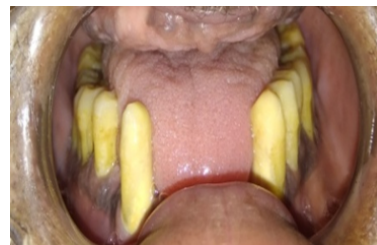

Fig. 2: Mandibular partially edentulous arch

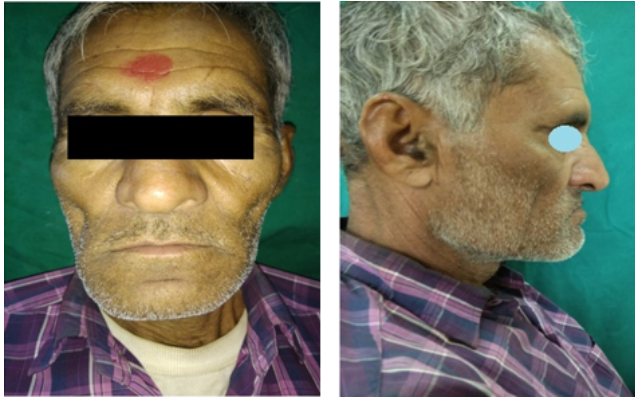

Fig. 3: Extra-oral photograph showing unsupported, sunken cheeks

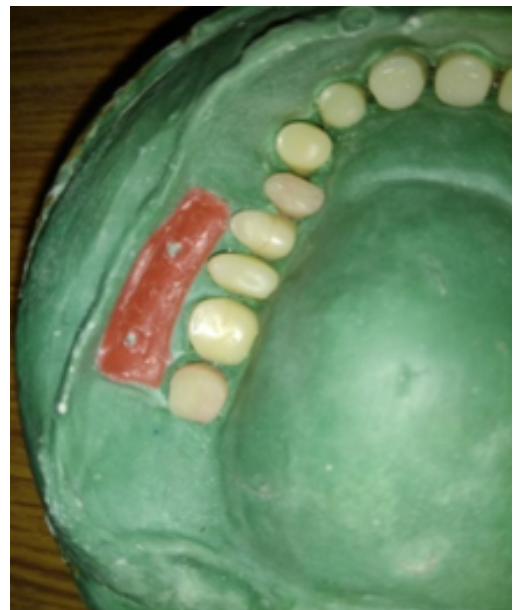

Fig. 6: Wax strip with orientation holes.



Fig. 4: Heat resistant, hollow PVC pipe (weight = 1.9 gm)

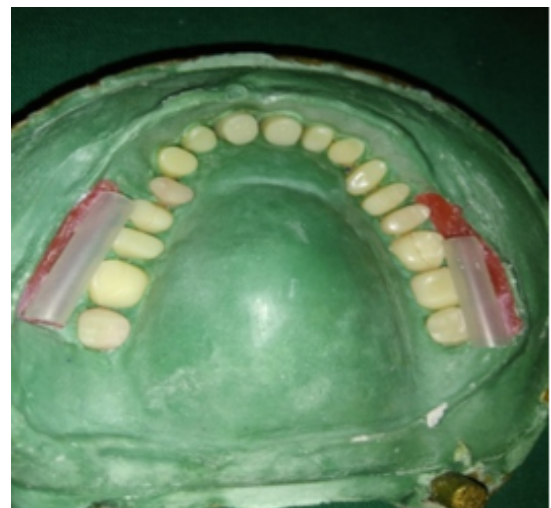

Fig. 7: Assembly until self cure plug sets and Wax-strip is later carefully removed



Fig. 5: Acrylic orientation plugs

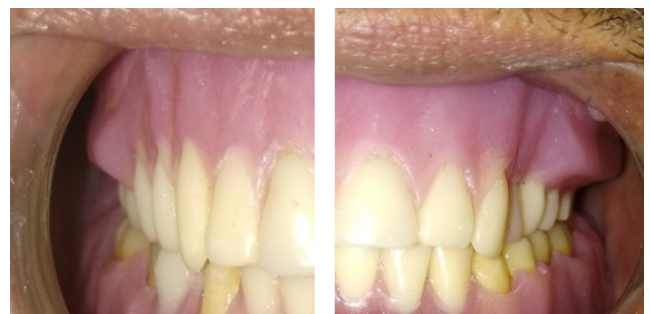

Fig. 8: Final prosthesis with hollow cheek plumpers of right and left side

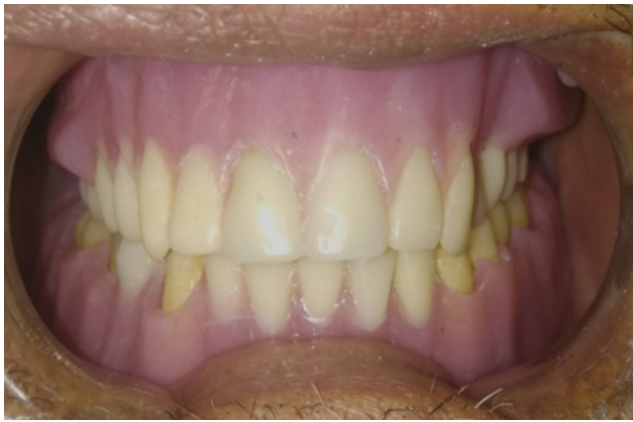

Fig. 9: Post-operative intra-oral photograph

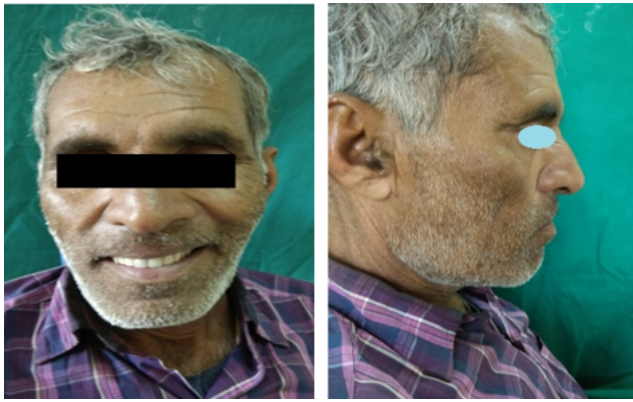

Fig. 10: Post-operative extra-oral photograph showing augmented cheeks

3. Discussion

Esthetics has become one of the salient elements in assuring success of any prosthodontic treatment. It is therefore important to understand and recognize various factors that affect facial appearance of the person.

Aging causes drastic alterations of face that includes tissue atrophy, thinning of skin and loss of subcutaneous fat, buccal fat pad, and exaggeration of creases and skin folds.³

Loss of teeth and alveolar ridge resorption in completely edentulous patients results in support-deprived oro-facial musculature, that collapses lower third of the face. The cheeks tend to move medially to meet the lateral encroaching tongue. This is also accompanied with deepening of naso-labial fold, depression of lips with evident wrinkles, drooped corners of mouth and loss of vermilion border, leaving the cheeks sunken and hollow. Also their form and contour are adversely affected due to loss of vertical dimension of occlusion.¹¹ Considering all the above factors, facial harmony and balance should be restored.

Despite of various treatment modalities available like, reconstructive plastic surgeries, botulinum toxin (BOTOX

procedure), rehabilitations through implants etc., using cheek plumpers with complete denture prosthesis is an easy, non-invasive and cost effective means to support and lift the oral and facial musculature which otherwise are flaccid and sunken. Construction of cheek plumpers makes additional use of denture base resin that elevates its overall weight. This hefty prosthesis has a detrimental effect on residual alveolar ridges that tend to resorb even faster under heavy load. Also, the increased weight amplifies the forces acting away from the foundation of maxillary arch, thereby interfering with denture retention.¹²

Therefore, in this case, the efforts were made to eliminate this extra weight by using light weight, heat resistant PVC pipes that rendered the prosthesis hollow in the region of cheek plumpers. Various other methods to create hollow cheek plumpers using salt, sugar, sawdust, and sand have also been discussed in the literature.^{13,14} However, unlike PVC pipes, these demand additional step of elimination and may be displaced to get incorporated in resin during compression moulding (packing) and final closure.

Initially, patient may find it difficult to insert and remove the prosthesis from the mouth but proper training and patient education with subsequent visits can overcome this problem easily.

4. Conclusion

It is the dentist's capability to acknowledge and understand the needs of the patient and accordingly formulate the treatment plan. The prosthodontic aid elaborated in this clinical report has not only tried to restore the lost oral functions but also facial esthetics ensuring the re-establishment of patient's mental, physical and social well being.

5. Acknowledgement

I would like to extend my gratitude to The Department of Prosthodontics and institution, Jaipur Dental College (MVGU) for providing necessary material and lab assistance for the case.

6. Source of Funding

None.

7. Conflict of Interest

None.

References

1. Bains JW, Elia JP. The role of facial skeletal augmentation and dental restoration in facial rejuvenation. *Aesthet Plast Surg.* 1994;18(3):243-6.
2. Zarb GA, Hobkirk J, Eckert S, Jacob R. Prosthodontic treatment for edentulous patients-e-book: complete dentures and implant-supported prostheses. Elsevier Health Sciences; 2013.

3. Martone AL. Effects of complete dentures on facial esthetics. *J Prosthetic Dent.* 1964;14(2):231-55.
4. Zwetckhenbaum SR, Shay K. Prosthodontic considerations for the older patient. *Dent Clin North Am.* 1997;41(4):817-45.
5. Jamieson CH. Geriatrics and the denture patient. *J Prosthetic Dent.* 1958;8(1):8-13.
6. Nariman RH, Sowmya MK, Krishna PD. A single complete denture with cheek plumpers to improve facial aesthetics. *J Dent Res Sci Dev.* 2015;2(1):17.
7. Lazzari JB. Intraoral splint for support of the lip in Bell's palsy. *J Prosthetic Dent.* 1955;5(4):579-81.
8. Mukohyama H, Kadota C, Ohyama T, Taniguchi H. Lip plumper prosthesis for a patient with a marginal mandibulectomy: a clinical report. *J Prosthetic Dent.* 2004;92(1):23-6.
9. Larsen SJ, Carter JF, Abrahamian HA. Prosthetic support for unilateral facial paralysis. *J Prosthetic Dent.* 1976;35(2):192-201.
10. Keni NN, Aras MA, Chitre V. Customised Attachments Retained Cheek Plumper Prosthesis: A Case Report. *J Indian Prosthodont Soc.* 2012;12(3):198-200.
11. Tautin FS. Denture esthetics is more than tooth selection. *J Prosthetic Dent.* 1978;40(2):127-30.
12. O'Sullivan M, Hansen N, Cronin RJ, Cagna DR. The hollow maxillary complete denture: A modified technique. *J Prosthetic Dent.* 2004;91(6):591-4.
13. Costa GD, Aras M, Chitre V, Rajagopal P, Nagarsekar A. Cheek Plumper with a Salivary Reservoir: An Esthetic and Functional Treatment Option for a Xerostomic Patient with Sunken Cheeks. *Dent.* 2015;05(293):2161-1122.
14. Sandebiksham P, Kumar CR, Rao DC, Kumar GS. Esthetics redefined by cheek props-A case report. *Ann Prosthodont Restor Dent.* 2017;3(2):73-80.

Author biography

Aarti Mehta Post Graduate Student

Sunil Kumar MV Professor

Harikesh Rao Professor and Head

Cite this article: Mehta A, Kumar MV S, Rao H. **Prosthetic augmentation of sunken cheeks using hollow PVC pipe cheek plumpers – A case report.** *IP Ann Prosthodont Restor Dent* 2020;6(3):157-161.